



Preliminary Report

Expanding Role of Orbital Decompression in Aesthetic Surgery

Mehryar Ray Taban, MD, FACS

Abstract

Background: Eye prominence is a source of cosmetic “deformity” for many patients not afflicted by Graves.

Objectives: To report our experience in using customized orbital decompression for purely aesthetic reason to reduce eye prominence in non-thyroid patients.

Methods: Retrospective analysis of patients undergoing cosmetic orbital decompression by one surgeon. Surgical technique included customized graded orbital bony-wall decompression (lateral-wall, basin, medial-wall, posterior-strut) and intraconal fat removal using eyelid crease and/or caruncle incisions. Inclusion criteria included any patient with relative prominent eye due to non-thyroid etiology. Preoperative and postoperative photographs at longest follow-up were used for analysis. Outcome measures included patient satisfaction (via a written questionnaire) and complication rates.

Results: Etiologies of prominent eyes included congenital shallow orbits (14), congenital hypoplasia of malar-eminence (5), enlarged globe from high myopia (5), buphthalmos (1), and relative proptosis from contralateral enophthalmos (1). Concurrent procedures included lower eyelid-retractors lysis (5), periocular fat injection (3), tear-trough implant (3), canthoplasty (3), and periocular filler injection (3). Mean patient age was 33.8 years (range, 19-60 years). The average follow-up was 9 months (range, 6 months-4 years). All 26 patients (11 males, 15 females) had reduction in globe prominence. The mean reduction in axial globe position was 3.1 mm (range, 1.5-6.2 mm). Twenty-four of 26 patients were satisfied with the surgical outcome, with 2 patients complaining of sunken eyes. No case of permanent diplopia occurred.

Conclusions: Orbital decompression may be done for cosmetic purpose, effectively and safely, to reduce eye prominence in non-thyroid patients by an experienced orbital surgeon.

Level of Evidence: 4

Editorial Decision date: November 16, 2016.



There are many people who are bothered by the appearance/prominence of their eyes and desire aesthetic improvement; they complain “my eyes don’t fit my face.” Although thyroid eye disease is a common cause of acquired prominent eyes, there are many other causes such as high myopic globes, shallow orbits with congenital proptosis, and congenital hypoplasia of the maxilla/zygoma, among other causes.

In addition to aesthetic issue of prominent eyes for the patient, the patient with a relatively prominent eye presents a challenge to the surgeon planning aesthetic or reconstructive surgery of the periocular tissues. When the globe is prominent relative to the orbital bony support, the

eyelids lose mechanical advantage, and there is a tendency toward scleral show, lagophthalmos, tear pump dysfunction with epiphora, and descent of the eyelid–cheek complex, especially if/when these patients undergo traditional

Dr Taban is an Assistant Clinical Professor, Division of Orbital and Ophthalmic Plastic Surgery, Jules Stein Eye Institute, David Geffen School of Medicine at UCLA, Los Angeles, CA. Dr. Taban is a plastic surgeon in private practice in Beverly Hills, CA.

Corresponding Author:

Dr Mehryar Ray Taban, 9735 Wilshire Blvd., Suite 319, Beverly Hills, CA 90212, USA.

E-mail: doctor@tabanmd.com

blepharoplasty. These disproportionate soft tissue bony relationships produce similar problems whether the proptosis is related to Graves disease, other active orbital process, enlarged globes (high myopia, buphthalmos, etc.), congenital shallow orbit with congenital proptosis, or congenital hypoplastic malar eminence with sclera show.^{1,2}

Eyelid camouflage procedures that address the soft tissues alone, such as lateral canthoplasty, lower eyelid retraction surgery, and orbital rim onlay implants, can be used to camouflage the globe prominence, but they are prone to failure if the underlying globe-orbit dystopia is not addressed.^{1,2} They are simply suboptimal compared to repositioning the globe appropriately within the orbital space. Osteotomy and bony advancement is a substantially invasive option with significant morbidity than could address the globe-orbit dystopia but is obviously not preferred. The gold standard for treating prominent eyes is orbital decompression surgery.

Orbital decompression has had a long historical association with Graves' exophthalmos as it is used to recess the globe relative to its bony support. However, orbital decompression has been shown to be of functional and cosmetic benefit to relative proptosis of non-thyroid origin, such as congenital shallow orbits, enlarged globes (high myopia, buphthalmos, etc.), and hypoplastic malar eminence with sclera show, by recessing the globe relative to its bony support.^{1,3-5} Regardless of etiology, (relative) proptosis can represent a disfiguring problem for the patient with potential functional sequel in the aging process, especially for those who elect to undergo cosmetic eyelid surgery in the future.

In this study, we report our experience in using customized orbital decompression for purely aesthetic reason to reduce eye prominence in non-thyroid patients.

METHODS

In this retrospective study, charts of patients undergoing cosmetic orbital decompression by one surgeon (M.T.) in private practice, from January 2012 to April 2016, were reviewed. Informed consent was obtained for each procedure, and the review adhered to the standards of the Declaration of Helsinki and was compliant with the Health Insurance Portability and Accountability Act, adherent to Institutional Review Board approval standards. Inclusion criteria included any patient with relative prominent eye due to non-thyroid etiology (enlarged globes from high myopia or buphthalmos, congenital shallow orbits, congenital hypoplasia of malar eminence, etc.). Concurrent complimentary procedures (periocular fat injection, tear trough implants, and/or lower eyelid retractors lysis) were recorded.

Orbital computerized tomography (CT) scan was obtained prior to surgery to analyze orbital bony anatomy and rule out other orbital pathology (tumor). Orbital

decompression was performed in graded customized fashion, based on the bony anatomy, amount of relative proptosis, the desired goal, and dynamic result of the surgery (based on intraoperative amount of globe retrodisplacement). The lateral orbital wall, inferior basin, and intraconal fat were addressed first, in graded fashion. If additional orbital space was needed, medial orbital wall and posterior strut and medial intraconal fat were removed, in graded fashion. The surgical technique has been reported previously, using hidden incisions including lateral upper eyelid crease incision (to approach the lateral orbital wall decompression and basin and inferolateral intraconal fat) and transcaruncular incision (for medial wall decompression and removal of posterior orbital strut and medial intraconal fat).⁶ Bilateral orbital decompressions were performed at the same encounter, if necessary. When indicated (Table 1), lower eyelid retractors lysis without spacer graft was performed concurrently to allow lower eyelid elevation.⁷ An animated video demonstrating the technique is available as Supplementary Material at www.aestheticsurgeryjournal.com.

Analysis included 26 patients. Three out of 26 patients had undergone previous orbital surgery (see results). Patients with less than 6-months follow-up were excluded.

Preoperative and postoperative photographs at longest follow-up visit were used for analysis. (All clinical photographs were obtained with written permission by the patient/guardian.) All photographs were obtained by the surgeon (M.T.) in standardized fashion with head in straight position and eyes looking directly into the camera, along with 45°, profile, and reverse bird-eye view. Outcome measures included patient satisfaction (via a written questionnaire) and complication rates after the latest postoperative follow-up appointment (average, 9 months; range, 6 months-4 years). A blank copy of the questionnaire is available as Supplementary Material at www.aestheticsurgeryjournal.com.

RESULTS

Etiologies of prominent eyes included congenital shallow orbits (14 patients) (as determined by preoperative CT scan and globe size and globe position), congenital hypoplasia of malar eminence (5 patients), enlarged globe from high myopia (5 patients), enlarged globe from buphthalmos (1 patient), and asymmetric globes from contralateral enophthalmos from trauma (1 patient). One patient had undergone previous orbital osteotomy and bony advancement with unsatisfactory result. Two patients had undergone previous limited orbital decompression (performed by another surgeon) with unsatisfactory results. The average follow-up after surgery was 9 months (range, 6 months-4 years).

Table 1. Summary of Clinical Findings in 26 Patients

Patient #	Age (years)	Gender	Ethnicity	Etiology of eye prominence	Decompression details	Adjunctive procedures	Complications/satisfaction
1	31	M	Middle-Eastern	Malar eminence hypoplasia and shallow orbits	Lateral wall (B) Medial wall (B) Posterior strut (B) Intraconal fat (B)	Tear trough implant, Lower lid retractors lysis without spacer graft, canthoplasty. Later had periocular HAG filler injection	None/Satisfied
2	20	F	Indian-English	High myopia	Lateral wall (B) Medial wall (B) Posterior strut (B) Intraconal fat (B)	None	None/Satisfied
3	23	M	Caucasian	High myopia	Lateral wall (B) Medial wall (B) Posterior strut (B) Intraconal fat (B)	None Later had periocular HAG filler injection	None/Satisfied
4	49	F	Caucasian	Shallow orbit H/o prior blepharoplasty with lid retraction	Lateral wall (B) Intraconal fat (B)	None	None/Satisfied
5	52	F	Caucasian	Malar eminence hypoplasia and shallow orbits	Lateral wall (B) Intraconal fat (B)	Tear trough implant, canthoplasty, periocular fat injection	None/Satisfied
6	37	M	Asian	Shallow orbits	Lateral wall (B) Intraconal fat (B)	None	None/Satisfied
7	28	F	Asian	Shallow orbits	Lateral wall (B) Intraconal (B) Medial wall (L)	Tear trough implants	None/Satisfied
8	26	F	African-American	Shallow orbits	Lateral wall (B) Medial wall (R) Intraconal fat (B)	Periocular fat injection	Asymmetry (one eye sunken more than other)/Unhappy about eye asymmetry
9	21	F	Caucasian (Swedish)	High myopia	Lateral wall (B) Medial wall (B) Intraconal fat (B)	None	Relative Enophthalmos (sunken eyes)/Unhappy about smaller eyes
10	31	M	Caucasian (German)	Malar eminence hypoplasia and shallow orbits H/o prior fatty orbital decompression	Lateral wall (L>R)	Periocular fat injection	None/Satisfied
11	23	F	Hispanic	Malar eminence hypoplasia and shallow orbits	Lateral wall (B) Intraconal fat (B)	Periocular fat injection	None/Satisfied
12	53	M	African-American	Shallow orbits and malar eminence hypoplasia	Lateral wall (B) Medial wall (B) Posterior strut (B) Intraconal fat (B)	Lower eyelid retractors lysis without spacer graft and canthoplasty	None/Satisfied
13	26	F	Asian	Shallow orbits	Lateral wall (B) Medial wall (B) Posterior strut (B) Intraconal fat (B)	None	None/Satisfied
14	21	F	Middle-Eastern	Malar eminence hypoplasia and shallow orbits	Lateral wall (R) Intraconal fat (R)	None	None/Satisfied
15	48	F	Turkish	High myopia, shallow orbits H/o prior lower blepharoplasty with lid retraction	Lateral wall (B) Medial wall (B) Posterior strut (B) Intraconal fat (B)	None	None/Satisfied

Table 1. (Continued)

Patient #	Age (years)	Gender	Ethnicity	Etiology of eye prominence	Decompression details	Adjunctive procedures	Complications/satisfaction
16	30	M	Caucasian	Shallow orbits	Medial wall (B) H/o previous osteotomy and bone advancement	None (later he had lower lid retractors lysis without spacer graft and canthoplasty)	None/Satisfied
17	33	M	Asian	Shallow orbits H/o prior lateral wall decompression	Lateral wall (B) Medial wall (B) Posterior strut (B) Intraconal fat (B)	None	None/Satisfied
18	32	F	Indian	High myopia, shallow orbits and malar eminence hypoplasia	Lateral wall (B) Medial wall (B) Posterior strut (B) Intraconal fat (B)	Lower lid retractors lysis without spacer graft	None/Satisfied
19	54	F	Persian	Shallow orbits and periocular atrophy H/o prior blepharoplasty with lid retraction	Lateral wall (B) Medial wall (R) Posterior strut (R) Intraconal fat (B)	None (later she had lower eyelid retraction surgery with Alloderm spacer graft)	None/Satisfied
20	26	M	Caucasian	Buphthalmos	Lateral wall (L) Medial wall (L) Posterior strut (L) Intraconal fat (L)	None	None/Satisfied
21	42	F	Caucasian	Shallow orbits	Lateral wall (B) Intraconal fat (B)	None	None/Satisfied
22	35	F	Caucasian	Contralateral enophthalmos from trauma	Lateral wall (R) Intraconal fat (R)	None	None/Satisfied
23	29	M	Asian	Shallow orbits H/o prior bony orbital decompression	Medial wall (B) Posterior strut (B) Intraconal fat (B)	None	None/Satisfied
24	19	M	Asian	Shallow orbits	Lateral wall (B) Medial wall (B) Posterior strut (B) Intraconal fat (B)	None	None/Satisfied
25	60	F	Asian	Shallow orbits H/o prior lower blepharoplasty with lid retraction	Lateral wall (B) Medial wall (R) Posterior strut (R) Intraconal fat (B)	None	None/Satisfied
26	31	M	Indian	Shallow orbits, plus malar eminence hypoplasia and high myopia	Lateral wall (B) Medial wall (B) Posterior strut (B) Intraconal fat (B)	None	None/Satisfied

B, bilateral; F, female; HAG, hyaluronic acid gel; h/o, history of; L, left; M, male; R, right.

The mean patient age was 33.8 years (range, 19-60 years). There were 11 males and 15 females. Concurrent procedures performed included periocular fat injection (3 patients), lower eyelid retractors lysis (5 patients), tear trough silicone implants (3 patients), lateral canthoplasty (3 patients), and periocular hyaluronic acid gel filler injection (3 patients). Additional details are available on [Table 1](#).

All 26 patients had reduction in globe prominence. The mean reduction in axial globe position (using Hertel's Exophthalmometer) was 3.1 mm (range, 1.5-6.2 mm). Twenty-four of 26 patients (92%) were satisfied with the surgical outcome. One patient complained of sunken eyes

and one patient complained of relative asymmetry with one eye more sunken than the other but neither patient elected for any further treatment. Six patients complained of temporary numbness along zygomaticofacial nerve distribution. No case of permanent diplopia occurred. Representative patient cases are shown in [Figures 1-2](#) and [Supplementary Figures 1-4](#).

DISCUSSION

Over the years, the threshold for performing reconstructive orbital surgery in Graves' patients has been lowered

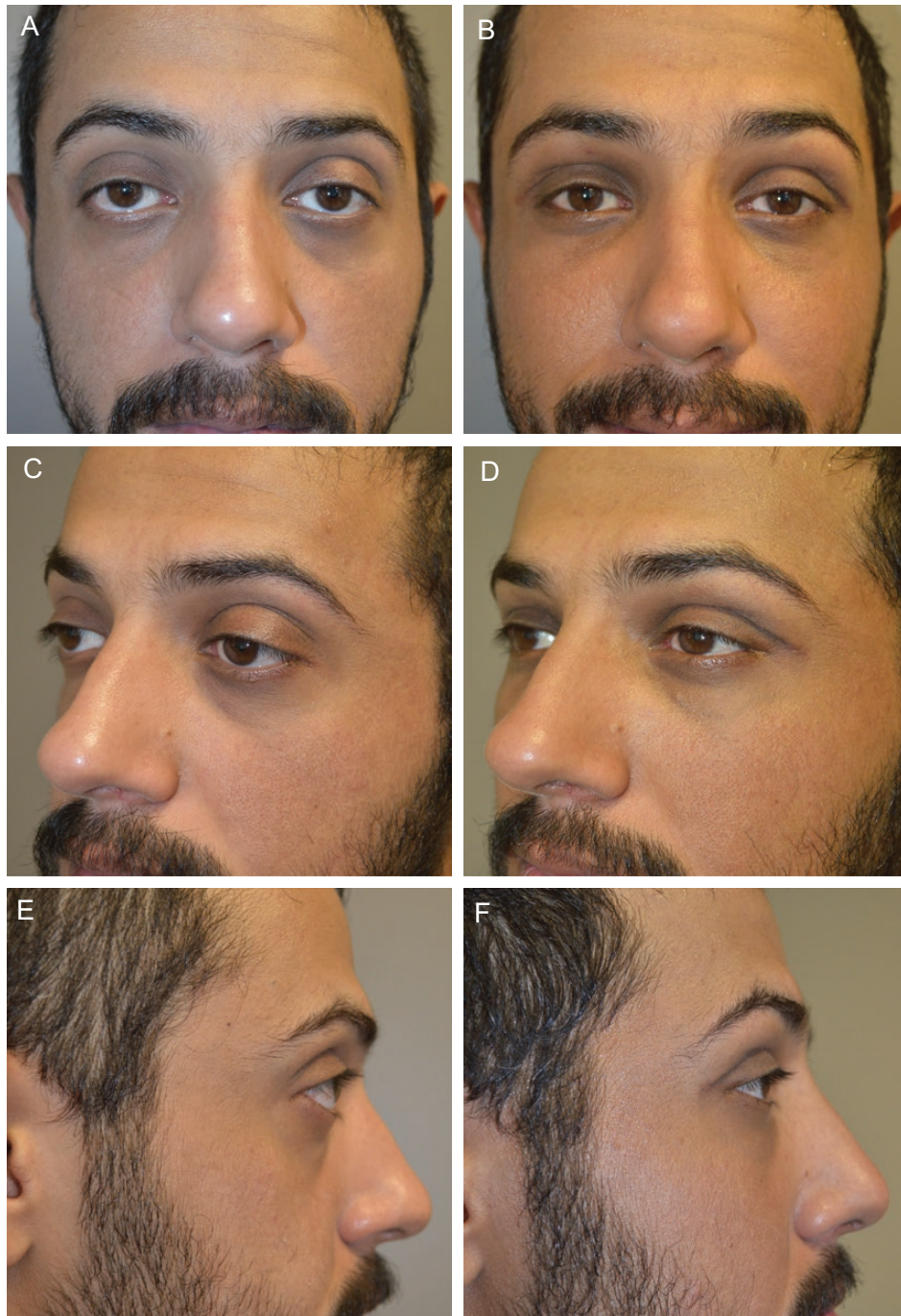

Figure 1. (A, C, E) Preoperative and (B, D, F) 7-month postoperative photographs of a 31-year-old Middle-Eastern man who complained of “frog eyes,” secondary to congenital shallow orbits, congenital malar eminence hypoplasia and lower eyelid retraction with sclera show. He underwent bilateral balanced lateral and medial wall decompression with posterior strut removal along with intraconal fat removal plus tear trough implants and lower eyelid retractors lysis (without spacer graft), followed later by periocular hyaluronic acid gel filler injection. The globes were retrodisplaced 4.5 mm.

by public demand.^{1,6} In this study, we demonstrated that orbital decompression surgery can be performed for purely cosmetic reasons to reduce prominent eyes, effectively and safely. It was also done on select patients with lower eyelid retraction as preparatory step prior to undergoing lower

eyelid retraction surgery as to allow the lower eyelid more favorable chance to be elevated. However, there are many important points that need discussed further here.

Any oculoplastic surgery carries risks associated with anesthesia, bleeding, and infection, but orbital surgery

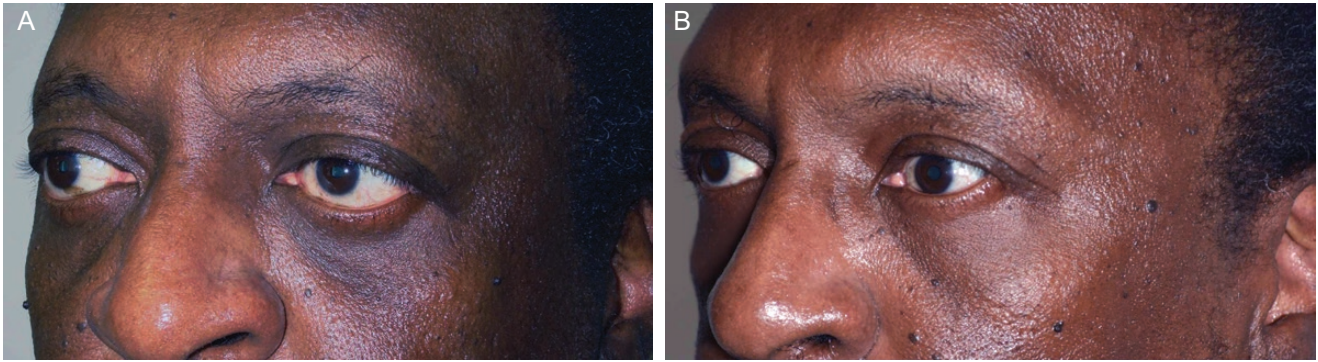


Figure 2. (A) Preoperative and (B) 2-year postoperative photographs of a 53-year-old African-American man who complained of bulging eyes, secondary to shallow orbits and malar eminence hypoplasia and lower eyelid retraction. He underwent balanced lateral and medial wall decompression with posterior strut removal and intraconal fat removal, plus lower eyelid retractors lysis (without spacer graft) and canthoplasty (tarsal strip method). The globes were retrodisplaced 4 mm.

incurs additional sight or life-threatening risks including diplopia, optic nerve damage, cerebrospinal fluid (CSF) leak and anesthesia risks.⁶ However, in skilled hands, the risk of optic nerve damage and CSF leak is extremely small. In regards to diplopia, there were no cases of diplopia in our series which is important to emphasize and it is due to many factors. First, healthy orbits with normal extraocular muscles, as opposed to unhealthy orbits in thyroid eye disease with fibrotic extraocular muscles and fat, are expected to be less prone to ocular misalignment. Second, there is greater flexibility and room to maneuver in the orbit in healthy orbits as opposed to fibrotic orbits in thyroid eye disease with expected reduction in complication rates. Third, newer techniques and philosophies have allowed us to be more confident of our ability to grade the decompression and reduce diplopia and other complications.⁶ The orbital floor decompression was performed on our study as it can lead to higher rate of diplopia and hypoglobus. Orbital decompression surgery has come a long way from the days it was done through a transcranial approach with high morbidity and complications to new techniques using hidden eyelid crease and conjunctival incisions with relatively quick outpatient recovery, with much reduced risks. Using graded approach, with lateral orbital wall decompression and intraconal fat removal as initial step followed by medial wall decompression (balanced orbital decompression) followed by posterior strut removal significantly minimize risk of diplopia in contrast to other techniques including transantral.^{6,8}

Although 24 of 26 patients in our series were satisfied with their treatment, 2 patients complained of eyes being too sunken (enophthalmos). As with all cosmetic procedures, the success is based on patient's desires and expectations. It goes without saying that careful history taking and awareness of psychological element are of paramount importance for the orbital surgeon who wants performs

orbital decompression for aesthetic reasons. Patients must accept the rare risk for serious complications. As with any other procedure, training, experience, and confidence are critical in achieving satisfactory results and minimizing complications. The decision to offer cosmetic orbital surgery should be based on the surgeon's confidence in his/her results and motivation to perform such surgery. The patient's psyche dominates his/her own motivation to have surgery and their response to surgical outcome.^{3,6} Once a decision to offer surgery is made, the aims, limitations, and complications need to be clear and confirmed in writing.

There are important limitations to our study that must be taken into account when considering the implications of the data. This is a retrospective, non-randomized study of a small number of patients with *various* orbital anatomy who underwent graded (*variable*) orbital decompression. The technique used is also based on the surgeon's personal training and experience. Additionally, a useful tool that was not used was three-dimensional imaging, which could be used for analysis of such results.⁹ Furthermore, the patient questionnaire consists of open-ended questions without scale for patient satisfaction. Lastly, there were some eyelid ancillary procedures performed that could affect the cosmetic outcome; however, the main purpose of the study is to shed light on expanding role of orbital decompression in non-thyroid patients for cosmetic purposes and report on its safety. I am not proposing that the only solution is orbital decompression for such patients as the eyelids and orbits and globes are all intricately related and ancillary procedures add, not take away, from the role of orbital decompression in such patients.

CONCLUSIONS

This study reported that orbital decompression may be done for cosmetic purpose, effectively and safely, to reduce eye

prominence in non-thyroid patients. Newer techniques and public demand have allowed such work to be done. We also propose that orbital decompression is easier and much safer to perform in this patient population given healthy orbits with non-fibrotic orbital contents. We propose that there is a potential for the *experienced* orbital surgeon to apply his/her skills to cosmetic orbital surgery. Cosmetic orbital decompression may be justified for those who have comfortable protruding eyes, which are sufficiently distressing to affect social interaction, after careful discussion of aims, limitations, and complications with awareness of their psychological element. Society can afford to value quality of life as well as working to lower morbidity and mortality.

Supplementary Material

This article contains supplementary material located online at www.aestheticsurgeryjournal.com.

Disclosures

The author declared no potential conflicts of interest with respect to the research, authorship, and publication of this article.

Funding

The author received no financial support for the research, authorship, and publication of this article.

REFERENCES

1. Goldberg RA, Hwang MM, Garbutt MV, Shorr N. Orbital decompression for non-Graves' orbitopathy: a consideration of extended indications for decompression. *Ophthalm Plast Reconstr Surg*. 1995;11(4):245-252; discussion 253.
2. Goldberg RA, Soroudi AE, McCann JD. Treatment of prominent eyes with orbital rim onlay implants: four-year experience. *Ophthalm Plast Reconstr Surg*. 2003;19(1):38-45.
3. Lane CM. Cosmetic orbital surgery. *Eye (Lond)*. 2006;20(10):1220-1223.
4. Krastinova-Lolov D, Bach CA, Hartl DM, et al. Surgical strategy in the treatment of globe protrusion depending on its mechanism (Graves' disease, nonsyndromic exorbitism, or high myopia). *Plast Reconstr Surg*. 2006;117(2):553-564.
5. Satchi K, McNab AA. Orbital decompression in the treatment of proptosis due to high axial myopia. *Ophthalm Plast Reconstr Surg*. 2010;26(6):420-425.
6. Goldberg RA. The evolving paradigm of orbital decompression surgery. *Arch Ophthalmol*. 1998;116(1):95-96.
7. Taban MR. Lower Eyelid Retraction Surgery Without Internal Spacer Graft. *Aesthet Surg J*. 2016 Sep 2. pii: sjw146. [Epub ahead of print]
8. Leone CR Jr, Piest KL, Newman RJ. Medial and lateral wall decompression for thyroid ophthalmopathy. *Am J Ophthalmol*. 1989;108(2):160-166.
9. Honrado CP, Larrabee WF Jr. Update in three-dimensional imaging in facial plastic surgery. *Curr Opin Otolaryngol Head Neck Surg*. 2004;12(4):327-331.