

Preliminary Report

# Lower Eyelid Retraction Surgery Without Internal Spacer Graft

Mehryar Ray Taban, MD, FACS

Aesthetic Surgery Journal  
2017, Vol 37(2) 133–136  
© 2016 The American Society for  
Aesthetic Plastic Surgery, Inc.  
Reprints and permission:  
journals.permissions@oup.com  
DOI: 10.1093/asj/sjw146  
www.aestheticsurgeryjournal.com  
**OXFORD**  
UNIVERSITY PRESS

## Abstract

**Background:** Internal eyelid spacer graft is routinely placed during lower eyelid retraction surgery, which may be unnecessary.

**Objectives:** To evaluate the efficacy of lower eyelid retraction surgery without internal graft in select cases.

**Methods:** Retrospective analysis of patients undergoing reconstructive lower eyelid retraction surgery without internal graft, by one surgeon from 2013 to 2015. Surgical technique included transconjunctival lower eyelid retractor lysis, canthoplasty, and temporary tarsorrhaphy, with or without subperiosteal midface-sub orbicularis oculi fat (SOOF) lifting and scar lysis. Eyelids with true lower eyelid middle-lamella shortage were excluded. Analysis included 17 surgeries (11 patients). Eight of 11 patients had undergone at least one previous lower eyelid surgery with resultant lower eyelid retraction and sclera show. Preoperative and postoperative photographs at longest follow-up visit were analyzed with standardized measurements. Patient satisfaction was recorded using questionnaire.

**Results:** Etiologies of lower eyelid retraction included prior lower blepharoplasty, thyroid eye disease, and chronic facial palsy. All 11 patients (17 procedures) demonstrated improvement of lower eyelid position. The mean improvement of marginal reflex distance was 2.2 mm (range, 1.6–2.8 mm). There was one case of mild overcorrection. The average follow-up was 7 months (range, 6 months–2 years). Midface lift was performed for 14 of 17 eyelids.

**Conclusions:** This study demonstrates improvement of lower lid position after lower eyelid retraction surgery without internal eyelid spacer graft in select patients. Most patients in our study had undergone previous lower eyelid blepharoplasty and required midface-SOOF lifting. The author proposes that “routine” placement of lower eyelid internal spacer/graft may not be necessary during lower eyelid retraction surgery.

Accepted for publication July 25, 2016; online publish-ahead-of-print September 2, 2016.

Lower eyelid retraction is defined as the inferior malposition of the lower eyelid margin with or without eyelid malrotation. It presents clinically with scleral show; round, sad-looking eyes; possible lateral canthal tendon laxity; which can result in symptoms of ocular irritation, including photophobia, excessive tearing, and nocturnal lagophthalmos. These patients may require frequent ocular lubricants which provide only minimal alleviation of these symptoms.<sup>1</sup> Patients are often unhappy about the eye appearance.

Severe eyelid malposition can occur following transcutaneous lower eyelid blepharoplasty in up to 15 to 20 percent of patients.<sup>2,3</sup> However, lower eyelid malposition can occur after any procedure which violates the lower eyelid including midface lifting procedures, fat re-draping, composite rhytidectomy, or fracture repair.<sup>1</sup> Other etiologies of lower eyelid retraction include thyroid eye disease with or without proptosis, chronic proptosis or prominent globes, chronic facial palsy, poor maxillary support, and congenital variants.

The lower eyelid is supported by the lateral and medial canthal tendons, the capsulopalpebral fascia (or lower lid

retractors), the tarsus, and the orbicularis oculi muscle.<sup>1,4</sup> The lower eyelid includes 3 lamella: anterior lamella (skin), middle lamella (orbicularis oculi muscle and septum and eyelid retractors), posterior lamella (tarsus and conjunctiva). Cicatricial lower eyelid ectropion occurs from anterior lamella contraction whereas lower eyelid retraction results from contracture or relative shortage of primarily the middle lamella, although other lamella layers could also be involved. Additional factors involved in lower eyelid malposition include midface descent, poor maxillary support, and prominent globe. Midface or sub orbicularis oculi fat (SOOF) descent in conjunction with cicatricial lower eyelid

Dr Taban is an Assistant Clinical Professor, Division of Orbital and Ophthalmic Plastic Surgery, Jules Stein Eye Institute, David Geffen School of Medicine at UCLA, Los Angeles, CA.

## Corresponding Author:

Dr Mehryar Ray Taban, MD, FACS, 9735 Wilshire Blvd, Suite 319, Beverly Hills, CA 90212, USA.  
E-mail: doctor@tabanmd.com

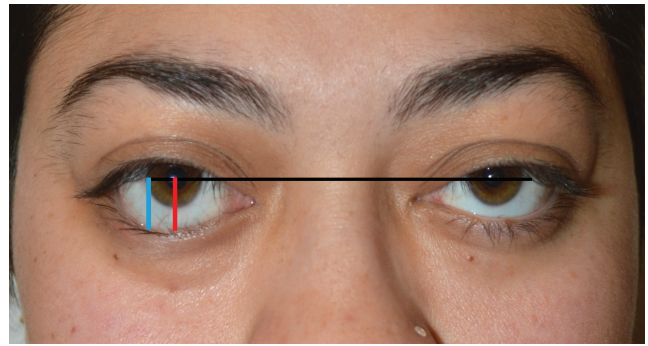
changes and large eye morphology cause severe lower eyelid malposition.<sup>5,6</sup>

Once the pathophysiology and anatomic cause of lower eyelid retraction is understood, it is much easier to understand how to correct it. Although a combined midface lift with lower eyelid spacer graft is required in the most challenging cases of lower eyelid retraction,<sup>7-11</sup> routine placement of spacer graft may not be necessary in all cases. The purpose of this study is to evaluate the efficacy of lower eyelid retraction surgery without the use of any internal graft in select cases.

## METHODS

In this retrospective study, charts of patients undergoing lower eyelid retraction surgery without placement of internal eyelid spacer graft by one surgeon (M.R.T.) in private practice from January 2013 to December 2015, were reviewed. Informed consent was obtained for each procedure, and the review adhered to the standards of the Declaration of Helsinki and was compliant with the Health Insurance Portability and Accountability Act, adherent to IRB approval standards. Surgical technique included transconjunctival lower eyelid retractors lysis (complete release of lower eyelid retractors attachment to the tarsus), canthoplasty, and temporary frost tarsorrhaphy, with or without middle lamellae scar lysis and sub-periosteal midface-SOOF lift. The technique is similar to previously published techniques,<sup>5,8-11</sup> except no spacer graft was placed. The latter step was performed in patients who had additional anterior lamella (skin) cicatrix (as determined by lower eyelid forced upward traction test), requiring recruitment of skin through midface/SOOF lifting. Eyelids with true middle lamella shortage (as evidenced by preoperative forced upward traction test), requiring internal spacer graft, were excluded from the study. (Preoperative lower eyelid forced upward traction test not only determines if there is cicatrix in the lower eyelid preventing it from elevating, it also determines what layer(s) of the lower eyelid the cicatrix exists. Initial step of this test involves manually pushing the lower eyelid up; normally the lower eyelid is able to be pushed up close to the upper limbus; if there is cicatrix, there is limitation of its elevation. Secondary step involves manually elevating the midface in addition to the lower eyelid with release of any skin cicatrix tension, thereby revealing presence of any true middle lamella cicatrix.)

Analysis included 17 surgeries in 11 patients. 8 out of 11 patients had undergone at least one previous lower eyelid surgery with resultant lower eyelid retraction and sclera show. Patients with <6-months follow-up were excluded. Patient satisfaction was recorded using questionnaire. In addition to customary questions/examination between the patient and the surgeon, a phone call was placed by the surgical coordinator to the patient after the latest postoperative follow up appointment.



**Figure 1.** The distances used in our calculations were the corneal diameter of respective sides along with the center of pupil to lower lid margin (central LD) and lateral limbus to lower lid margin (lateral LD), as demonstrated on this 25-year-old woman.

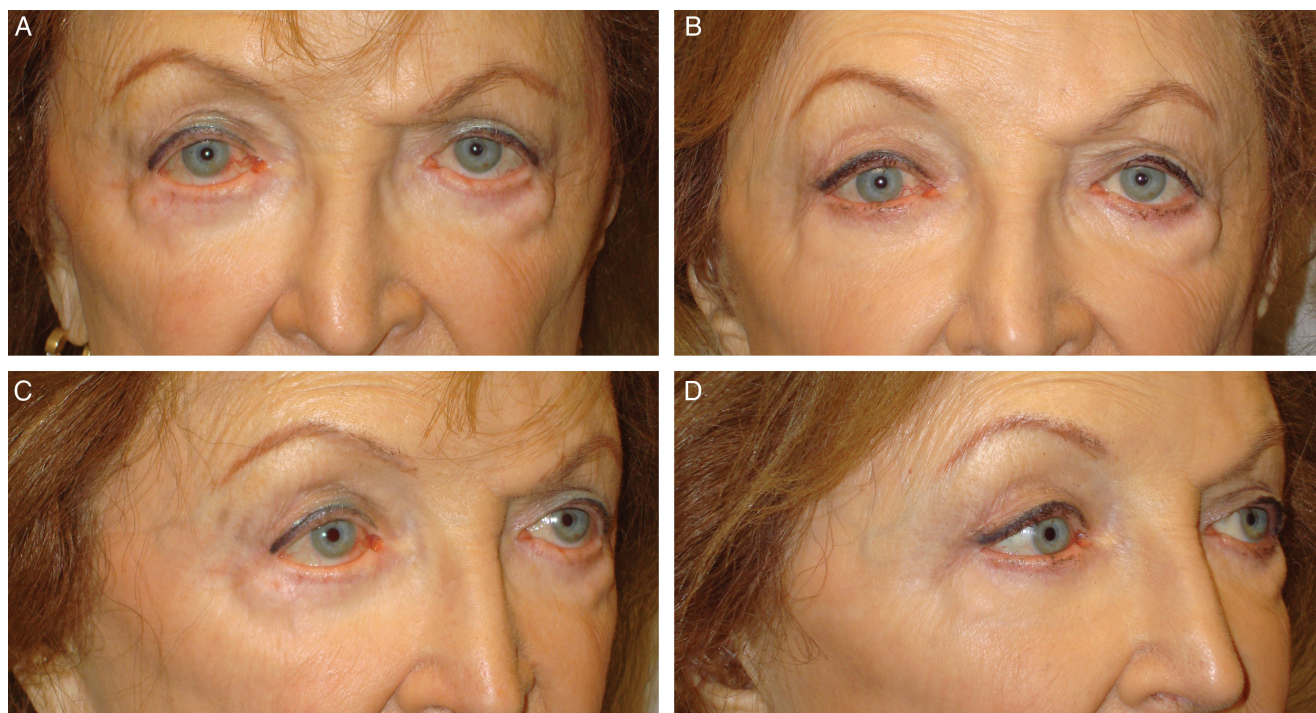
Preoperative and postoperative photographs at longest follow-up visit were used for analysis. All photographs were obtained by the surgeon in standardized fashion with head in straight position and eyes looking directly into the camera. Measurements of the corneal diameter and distance from pupil center to lower lid margin were obtained, standardized, and compared, per previous protocol (Figure 1).<sup>11</sup>

## RESULTS

Etiologies of lower eyelid retraction included prior lower blepharoplasty (8 patients), thyroid eye disease (2 patients), and chronic facial palsy (1 patient). The mean patient age was 45 years (range, 25-85 years). There were 10 females and 1 male. Midface-SOOF lifting was performed in 14 of 17 eyelids. All 11 patients (17 procedures) demonstrated improvement of lower eyelid position. There was one case of mild over-correction. Subjective patient satisfaction was high in all cases except the case of mild over-correction. Representative examples are shown in Figure 2 and Supplementary Figures 1-3 (available as [Supplementary Material at www.aestheticsurgeryjournal.com](http://www.aestheticsurgeryjournal.com)). The mean preoperative MRD<sub>2</sub> was 6.6 mm (range, 6.1-8 mm) and the mean postoperative MRD<sub>2</sub> was 4.4 (range, 4.0-5.2 mm). The mean improvement or change in eyelid height was 2.2 mm (range, 1.6-2.8 mm). The average follow-up after surgery was 7 months (range, 6 months-2 years).

## DISCUSSION

Despite advances and knowledge in lower blepharoplasty techniques,<sup>1,10-17</sup> postoperative lower eyelid retraction still occurs, with functional and cosmetic problems, which is especially bothersome for the patient and surgeon as these patients had underwent lower blepharoplasty for cosmetic reasons. In addition to post-blepharoplasty lower eyelid retraction, other lower eyelid retraction etiologies include thyroid eye disease with or without proptosis, long-term



**Figure 2.** (A, C) Preoperative and (B, D) 2 year postoperative photographs of a 70-year-old woman with right lower eyelid cicatricial retraction secondary to prior transcutaneous lower blepharoplasty. She underwent transconjunctival lower eyelid retractors lysis, midface/SOOF lift, open canthoplasty, and temporary tarsorrhaphy.

proptosis or prominent globes, long-term facial palsy, poor maxillary support, and congenital variants.

There have been many studies and different procedures proposed to correct lower eyelid retraction, with the use of variable internal eyelid spacer grafts, including hard palate, ear cartilage, fascia, Alloderm, Enduragen, donor sclera, among others.<sup>4,16,18-26</sup> Eyelid spacer grafts have a definite role in cases with true lower eyelid middle lamella cicatrix/shortage to provide additional augmentation by lengthening the lower-lid retractors and giving vertical height and stiffness to support the lower eyelid following release of the cicatrix.<sup>11</sup> However the benefits of reconstructive cosmetic eyelid surgery must always be weighed against many other factors. Use of spacer grafts is associated with increased surgical time, increased surgical cost, possible donor site morbidity, graft complication, and increased recovery time. Therefore, their use should be limited to cases that truly need middle lamella support. Previous studies have shown spacer graft may not be necessary in mild cases of eyelid retraction due to orbicularis oculi weakness.<sup>27-29</sup> However, no previous study has been done to analyze the effect of eyelid retraction surgery without spacer in moderate to severe cases of eyelid retraction, specifically due to previous eyelid operations (ie, lower blepharoplasty) with resultant anterior lamella +/- middle lamella cicatrix, with required midface/SOOF lifting. Similar cicatricial process is responsible for lower eyelid retraction

in thyroid eye disease patients and in some patients with chronic facial palsy.

In the current study of lower eyelid retraction surgery without internal spacer graft, the lower eyelid was elevated to normal position in nearly all cases. There are important limitations to our study that must be taken into account when considering the implications of the data. The patients were not randomized. There were also various decisions made that can be confusing. First, the decision to perform midface lifting was based on need for anterior lamella which can be difficult to standardize. Second, the decision to not place internal spacer graft was based on lack of need for middle lamella support (as determined using forced upward traction test during preoperative examination), which is again difficult to standardize. Furthermore, although good quality photographic documentation was available at regular intervals for all patients, allowing quantitative and unbiased evaluation, measurements taken from photographs have inherent inaccuracy. Lastly, longer-term follow ups are lacking than those already included.

## CONCLUSIONS

This study demonstrates improvement of lower lid position after lower eyelid retraction surgery without the use of internal eyelid spacer graft during lower eyelid reconstruction in select patients of cicatricial lower eyelid retraction. Our

results are comparable to previous studies that have used internal spacer grafts in all cases.<sup>11</sup> Most patients in our study who had undergone previous lower eyelid blepharoplasty with resultant midface/middle lamellae tethering did require subperiosteal midface lifting with scar release. The author believes lower eyelid spacer grafts are overused. He proposes that “routine” placement of lower eyelid internal spacer graft may not be necessary during lower eyelid retraction surgery, thereby reducing surgical time, reducing surgical cost, reducing graft complications and morbidity, and speeding up recovery time.

## Supplementary Material

This article contains Supplementary Material located online at [www.aestheticsurgeryjournal.com](http://www.aestheticsurgeryjournal.com).

## Disclosures

The author declared no potential conflicts of interest with respect to the research, authorship, and publication of this article.

## Funding

The author received no financial support for the research, authorship, and publication of this article.

## REFERENCES

1. Patipa M. The evaluation and management of lower eyelid retraction following cosmetic surgery. *Plast Reconstr Surg*. 2000;106:438-459.
2. Neuhaus R, Baylis H. Complications of lower eyelid blepharoplasty. In: Putterman AM, ed. *Cosmetic Oculoplastic Surgery*. New York: Grund Stratton, 1982.
3. McGraw BL, Adamson PA. Postblepharoplasty ectropion. *Arch Otolaryngol Head Neck Surg*. 1991;117:852-856.
4. Kersten RC, Kulwin DR, Levartovsky S, et al. Management of lower-lid retraction with hard-palate mucosa grafting. *Arch Ophthalmol*. 1990;108:1339-1343.
5. Shorr N. Madame Butterfly procedure with hard palate graft: management of post-blepharoplasty round eye and scleral show. *Facial Plast Surg*. 1994;10:90-118.
6. Patel BCK, Patipa M, Anderson RL, McLeish W. Management of post-blepharoplasty lower eyelid retraction with hard palate grafts and lateral tarsal strip. *Plast Reconstr Surg*. 1997;99:1251-1260.
7. McCord CDJ, Ellis DS. The correction of lower lid malposition following lower lid blepharoplasty. *Plast Reconstr Surg*. 1993;92:1068-1072.
8. Shorr N, Fallor MK. Madame Butterfly Procedure: Combined cheek and lateral canthal suspension procedure for post-blepharoplasty, round eye, and lower eyelid retraction. *Ophthal Plast Reconstr Surg*. 1985;1:229-235.
9. Cohen MS, Shorr N. Eyelid reconstruction with hard palate mucosa grafts. *Ophthal Plast Reconstr Surg*. 1992;8:183-195.
10. Shorr N, Perry JD, Goldberg RA, et al. The safety and applications of acellular human dermal allograft in ophthalmic plastic and reconstructive surgery. *Ophthal Plast Reconstr Surg*. 2000;16:223-230.
11. Taban M, Douglas R, Li T, et al. Efficacy of thick acellular human dermis (alloderm) for lower eyelid reconstruction. *Arch Facial Plast Surg*. 2005;7:38-44.
12. McCord CD Jr, Shore JW. Avoidance of complications in lower lid blepharoplasty. *Ophthalmology*. 1983;90:1039-1046.
13. Edgerton MT Jr. Causes and prevention of lower eyelid ectropion following blepharoplasty. *Plast Reconstr Surg*. 1972;49:367-373.
14. Tenzel RR. Complications of blepharoplasty, orbital hematoma, ectropion and scleral show. *Clin Plast Surg*. 1981;8:797-802.
15. Zarem HA, Resnick JJ. Expanded applications for transconjunctival lower lid blepharoplasty. *Plast Reconstr Surg*. 1991;88:215-220.
16. Kim JW, Ellis DS, Stewart WB. Correction of lower eyelid retraction by transconjunctival retractor excision and lateral eyelid suspension. *Ophthal Plast Reconstr Surg*. 1999;15:341-348.
17. Goldberg RA, Lessner AM, Shorr N, Baylis HI. The transconjunctival approach to the orbital floor and orbital fat. A prospective study. *Ophthal Plast Reconstr Surg*. 1990;6:241-6.
18. Henderson JW. Relief of eyelid retraction. *Arch Ophthalmol*. 1965;74:205-216.
19. Harvey JT, Anderson RL. The aponeurotic approach to eyelid retraction. *Ophthalmology*. 1981;88:513-524.
20. Baylis HI, Nelson ER, Goldberg RA. Lower eyelid retraction following blepharoplasty. *Ophthal Plast Reconstr Surg*. 1992;8:170-175.
21. Rubin PA, Fay AM, Remulla HD, Maus M. Ophthalmic plastic applications of acellular dermal allografts. *Ophthalmology*. 1999;106:2091-2097.
22. Holt JE, Holt GR, Van Kirk M. Use of temporalis fascia in eyelid reconstruction. *Ophthalmology*. 1984;91:89-93.
23. Obear MF, Smith B. Tarsal grafting to elevate the lower lid margin. *Am J Ophthalmol*. 1965;59:1088-1090.
24. Doxanas MT, Dryden RM. The use of sclera in the treatment of dysthyroid eyelid retraction. *Am J Ophthalmol*. 1981;88:887-894.
25. Baylis HM, Rosen N, Neuhaus RW. Obtaining auricular cartilage for reconstructive surgery. *Am J Ophthalmol*. 1982;93:709-712.
26. Siegel RJ. Palatal grafts for eyelid reconstruction. *Plast Reconstr Surg*. 1985;76:411-414.
27. Compton CJ, et al. Recession and extirpation of the lower eyelid retractors for paralytic lagophthalmos. *Ophthal Plast Reconstr Surg*. 2015;31:323-324.
28. Yoo DB, et al. The minimally invasive, orbicularis-sparing, lower eyelid recession for mild to moderate lower eyelid retraction with reduced orbicularis strength. *JAMA Facial Plast Surg*. 2014;6:140-146.
29. Norris JH, Malhotra R. Composite septo-retractor recession; a surgical technique for lower-eyelid retraction and review of the literature. *Ophthal Plast Reconstr Surg*. 2011;27:447-452.