

Washington University School of
Medicine Interlibrary Loan



ILLiad TN: 211561

Borrower: OHUCVS

Lending String:

Patron: Taban, Mehryar - TN; 73669

Journal Title: Comprehensive ophthalmology
update

Volume: 7 **Issue:** 5

Month/Year: 2006 **Pages:** 205-12

Article Author: Taban M;Chen B;Perry J

Article Title: Update on punctal plugs.

Imprint:

ILL Number: 21396952



Call #:

Location:

ARIEL

Charge

Maxcost: \$50.00

Shipping Address:

Alumni Library Interlibrary Loan Departm
Cleveland Clinic Foundation
9500 Euclid Avenue
Cleveland, OH 44195-5243

Fax: 1.216.444-0271

Ariel: 64.40.17.85/192.35.79.34

Regular

DOCLINE NOTES:

CLINICAL PRACTICE

Update on Punctal Plugs

MEHRYAR TABAN, MD, BENSON CHEN, MD, AND JULIAN D. PERRY, MD

Abstract. Punctal plugs have offered a safe and often reversible treatment for aqueous-deficient dry eye for over three decades. However, they represent only one tool in our armamentarium to help patients with dry eyes, and plugs do have limitations. This article briefly reviews the history of occlusive treatments for aqueous tear deficiency and provides an update of recent advancements in punctal and canalicular occlusive materials and techniques. (*Comp Ophthalmol Update* 7: 205-12, 2006)

Key words. canalicular plug • dry eye • punctal occlusion • punctal plug

Introduction

Punctal plugs have offered a safe and often reversible treatment option for aqueous-deficient dry eye for over three decades.¹ This article briefly reviews the history of occlusive treatments for aqueous tear deficiency and provides an update of recent advancements in punctal and canalicular occlusive materials and techniques.

benefit from permanent closure.³ Freeman developed the first reversible, long-term occlusive treatment using nondissolving punctal plugs in 1975.¹

Over the past three decades, modifications to plug design and position have improved comfort and retention while minimizing complications. A wide variety of temporary and permanent materials are now available in different shapes for punctal or intracanalicular placement.

Brief History

In 1935, Beetham reported the first successful treatment of dry eye symptoms by cautery occlusion of the tear drainage system.² Unfortunately, some patients developed epiphora from this permanent procedure. In 1961, Foulds proposed the use of dissolvable gelatin plugs prior to cautery to test which patients would

Indications

Dry eye syndrome, or keratoconjunctivitis sicca, has been defined as a tear film abnormality resulting from either inadequate secretion or excessive evaporation, leading to ocular surface damage or discomfort.⁴ The cyclic nature of ocular surface and lacrimal gland inflammation, combined with

Dr.s. Taban, Chen, and Perry are affiliated with the Division of Ophthalmology, Cole Eye Institute, the Cleveland Clinic Foundation, Cleveland, OH.

Reprint address: Division of Ophthalmology, Cole Eye Institute, Desk I-32, the Cleveland Clinic Foundation, 9500 Euclid Ave., Cleveland, OH 44195
email: perryj1@ccf.org

TABLE 1
Ocular Conditions Shown to Benefit from Punctal Occlusion.⁸

Dry eye syndrome
Penetrating keratoplasty
Superior limbic keratoconjunctivitis
Neurotrophic keratitis
Ocular cicatrizing disease
Recurrent erosion syndrome
Seventh nerve palsy
Thyroid eyelid retraction
Postblepharoplasty eyelid retraction
Lagophthalmos
Persistent epithelial defect
Toxic epitheliopathy
Contact lens intolerance
Steven-Johnson syndrome

disruption of the normal reflex tearing feedback loop, often results in a highly variable association between discomfort and damage.⁵ This lack of congruity between disease symptoms and signs complicates management and compliance.⁶ Lacrimal outflow occlusion often offers more continuous relief, particularly for those patients who experience difficulty with topical therapy.

The defense of the corneal surface consists of an extraordinarily intricate system regulating tear secretion and blink rate (Figure 1). Normally, only 10% of secreted tears evaporate, while 90% typically drain into the nasolacrimal sac.⁷ Punctal occlusion results in several immediate advantages. Increasing the tear lake volume provides aqueous support and prolongs the duration and amount of contact between the corneal epithelium and local growth factors and immunomodulatory cytokines.

A complex of sensory, sympathetic, and parasympathetic nerves links the lacrimal system into a homeostatic loop; its essential role is to protect and support the ocular surface. This homeostatic loop may ultimately limit the improvement achieved with lacrimal outflow occlusion. Punctal occlusion in normal subjects may decrease tear production and ocular surface

sensation to invoke an autoregulatory mechanism that returns tear production, tear clearance, and ocular surface sensation to preocclusion levels 14 days to 17 days after punctal occlusion.⁸ Corneal sensation, modulated through bradykinin and substance P secretion, tear nerve growth factor (NGF) levels, and neuronal nitric oxide synthase may play a role in modulating tear production.^{8,9} While future treatments should solve aqueous-deficient dry eye by modulating this autoregulatory mechanism, punctal plugs currently offer relief for many patients.

When considering punctal occlusion, other patient parameters affect occlusive treatment decisions. For example, female patients with similar aqueous-deficiency testing parameters as males may require more aggressive treatment. Significant reflex secretion may allow for occlusion of only the lower punctum, while its absence may call for both lower and upper outflow occlusion.

Numerous other disorders of the ocular surface may benefit from tear drainage occlusion as well (Table 1).¹⁰ Occlusion also enhances the efficacy and safety of topical ocular medications by prolonging ocular availability and decreasing systemic absorption.^{11,12} Temporary occlusion treats causes of transient dry eye and

predicts efficacy and tolerance of more permanent occlusive procedures.¹³ It can optimize tear volume and quality during the early postoperative period after LASIK. Symptomatic partial punctal stenosis may be improved by insertion of a modified punctal plug perforated with a hollow lumen.^{14,15} These modified punctal plugs can widen the drainage passage, and the lumen may allow for more outflow than the stenotic punctum.

Contraindications

Lacrimal drainage occlusive devices are contraindicated in patients with known allergy to the device material (silicone, bovine collagen, glycolic acid, trimethylene carbonate, etc.). Patients with signs of ocular infection or irritation (blepharitis or meibomian gland dysfunction) require further evaluation and treatment before considering tear drainage occlusion, as occlusion may increase local cytokines to increase irritation and epithelial destruction. Epiphora due to lacrimal drainage obstruction contraindicates placement of a lacrimal occlusive device.

Objective Measurements

While punctal and canalicular occlusion often provide relief of symptoms from aqueous tear deficiency, objective tests to reach the diagnosis and assess possible benefits of occlusion should be considered. Schirmer testing can be used to diagnose abnormal tear secretion.¹⁶

Focus Point #1

Recent modifications in plug design allow for increased tolerance and retention.




Fig. 1. Yin-Yang of a balanced lacrimal tear film.

Tear clearance can be assessed by the dye disappearance test to rule out lacrimal outflow obstruction as the cause of epiphora. Surface vital staining (fluorescein, lissamine green, rose bengal) and conjunctival impression cytology (decreased goblet cells, increased nucleocytoplasm ratio) confirm ocular surface damage.^{17,18} Histologic improvements with punctal occlusion may take much longer than symptomatic relief.¹⁹

Because the tear film and cornea work together as a focusing lens, visual acuity can provide a quantitative measure of ocular surface dysfunction when acuity is diminished in the absence of other causes. Continuous visual acuity measurements improve after lacrimal occlusion,²⁰ and can help determine the need for further occlusive therapy. Tear quality can be assessed by the tear break-up time (BUT), which typically improves after punctal occlusion.²¹ Tear meniscus height, an indicator of tear volume, also improves after occlusion.²² Punctal occlusion increases tear quality by normalizing tear lactoferrin, lysozyme, osmolarity, IgA and albumin levels, although these measurements are not typically used clinically.^{23,24}

While objective measures can help determine the need for and success of punctal occlusion therapy, subjective symptoms often guide

therapy. Objective measures can underestimate symptoms, and a self-assessment questionnaire better measures symptoms and response to therapy.²⁵ Symptoms may also point to the likely response to plug therapy. In our experience, epiphora due to hypersecretion responds well to plug placement, while photophobia, which may be due to underlying inflammation, does not. Symptoms suggestive of underlying surface inflammation should be corrected prior to punctal plug placement.

Lacrimal Occlusive Devices

ABSORBABLE INSERTS: INTRACANALICULAR (VERTICAL OR HORIZONTAL)

Absorbable intracanalicular implants provide for safe and temporary relief of aqueous-deficient dry eyes. These temporary plugs were originally developed to predict the efficacy and tolerance of the more permanent occlusive procedures, such as electrocautery and silicone punctal plugs. A wide range of materials has been used, including gelatin,³ gut suture,²⁶ and

collagen plugs,²⁷ among others.²⁸ Collagen intracanalicular plugs come in a range of lengths (1.6 mm to 3 mm) and diameters (0.2 mm to 0.6 mm). The intracanalicular location allows for flexible sizing and avoids the discomfort associated with punctal dilation. Typical insertion techniques begin with instilling a drop of topical anesthetic. The rod-shaped implants can then be inserted under slit-lamp magnification using jeweler's forceps. Careful complete insertion into the vertical or horizontal canaliculi prevents ocular surface irritation.

Although reports show highly variable absorption rates, dry eye symptoms typically improve for 1-2 weeks. Patients are instructed to record symptoms and the need for supplemental lubrication for the first few days after insertion. Evidence of intolerance, including signs of allergies or epiphora, should be noted. Collagen plugs may improve dry eye parameters in similar amounts as silicone plugs in the short term, and satisfaction with intracanalicular collagen plugs can predict relief of symptoms with punctal plugs.²⁹ However, intracanalicular plugs only partially occlude outflow, so some patients who tolerate absorbable plugs can still develop epiphora with more permanent plugs.^{22,30}

Newer, slower absorbing materials, such as PCL (E-caprolactone-L-lactide copolymer), monofilament (UltraPlug™, Surgical Specialties Corporation, Reading, PA), and the Extended Duration intracanalicular plug (Oasis Medical, Glendora, CA), offer similar ease of insertion, and last up to 6 months. The ProLong™ absorbable plug (FCI Ophthalmics, Marshfield Hills, MA), a copolymer of glycolic acid and trimethylene

Focus Point #2

Numerous ocular surface disorders may benefit from lacrimal drainage occlusion.

TABLE 2
List of Commercially Available Punctal and Canalicular Plugs

Plug Name	Manufacturer	Material/Absorbability	Location	Advantages/Disadvantages	Other Remarks
Herrlick Lacrimal Plugs®	Lacrimedics, Inc. Eastsound, WA	Either polydioxanone absorbable (~6 months) or silicone nonabsorbable	Horizontal canaliculus	No punctal dilation required	Sizes: 0.3, 0.5, 0.7 mm
Form Fit™	Oasis Medical, Glendora, CA	Hydrogel (absorbs tears), absorbable	Vertical canaliculus	One size fits all; low extrusion; removed by flushing punctum	Conforming
Extended Duration	Oasis Medical, Glendora, CA	Absorbable (~90 days)	Intracanalicular	N/A	Three sizes: 0.3, 0.4, 0.5 mm in diameter
Oasis Silicone Plugs	Oasis Medical, Glendora, CA	Silicone, nonabsorbable	Punctal	Preloaded or nonloaded	Sizes: 0.4–0.8 mm
SmartPlug™ (updated)	Medennium, Irvine, CA	Thermo-sensitive acrylic polymer, absorbable	Vertical canaliculus	Small box (storage); no punctal dilation required; difficulty reversal	Conforming
UltraPlug™	Surgical Specialties Corporation, Reading, PA	PCL monofilament, absorbable	Intracanalicular	N/A	Three sizes
Atelocollagen	Koken Bioscience Institutes, Japan	Injectable bovine dermis extract, absorbable	Intracanalicular	N/A	N/A
Snug Plug (FDA approval pending)	FCI Ophthalmics, Marshfield Hills, MA	Silicone, nonabsorbable	Punctal	One size fits all; no punctal dilation required; preloaded; one-step insertion	N/A
ProLong™	FCI Ophthalmics, Marshfield Hills, MA	Absorbable copolymer (~3 months)	Punctal	Ideal for post-LASIK	Three sizes: 0.3, 0.4, 0.5 mm in diameter and 2.0 in length
Ready-Set	FCI Ophthalmics, Marshfield Hills, MA	Silicone, nonabsorbable	Punctal	N/A	7 sizes (0.4–1.0 mm)
PVP Perforated Plugs	FCI Ophthalmics, Marshfield Hills, MA	Silicone with PVP coating	Punctal	For partial occlusion or stenosis	Sizes: 0.7 mm and 0.9 mm
SuperEagle™	Eagle Vision, Memphis, TN	Silicone, nonabsorbable	Punctal	Newest; good retention and comfort	Three sizes (range 0.4–1.1 mm)
SuperFlex™	Eagle Vision, Memphis, TN	Silicone, nonabsorbable	Punctal	Good retention and comfort; easy insertion; multiple sizes	8 sizes (0.4–1.1 mm)
Flow Controller	Eagle Vision, Memphis, TN	Silicone, nonabsorbable	Punctal	For partial punctal occlusion; tapered shaft	4 sizes (0.5–0.8 mm)
Eagle FlexPlug™	Eagle Vision, Memphis, TN	Silicone, nonabsorbable	Punctal	Flexible; good fit and comfort	8 sizes (0.4–1.1 mm)
EaglePlug™	Eagle Vision, Memphis, TN	Silicone, nonabsorbable	Punctal	Original plug; inexpensive	5 sizes (0.4–0.8 mm)
DuraPlug™	Eagle Vision, Memphis, TN	PCL, absorbable (60–180 days)	Punctal-canalicular	Ideal for post-LASIK	N/A
Parasol® Plus™ Occluder	Odyssey Medical, Inc., Memphis, TN	Silicone, nonabsorbable	Punctal	N/A	Sizes: small (0.4 mm) to extra-large (0.9 mm)
Parasol® Punctal Occluder	Odyssey Medical, Inc., Memphis, TN	Silicone, nonabsorbable	Punctal	Self-dilating plug	Sizes: extra-small (0.2 mm) to large (0.9 mm)
Quintess™	Cynacon/Ocusoft, Inc., Richmond, TX	Silicone, nonabsorbable	Punctal	Minimal foreign body sensation	Sizes: 0.3–0.9 mm
Collagen	Various manufacturers	Collagen, absorbable (days)	Punctal	For trial of punctal occlusion	N/A

carbonate, lasts up to 3 months. Recent reports describe canalicular Atelocollagen (Koken Bioscience Institutes, Japan) injection producing outflow occlusion for up to 8 weeks.^{31,32} The material is extracted from bovine dermis, and enzymatic processing removes the antigenic portions from the collagen molecule to create a well-tolerated injectable solution used to augment soft tissue defects.³³ The intracanalicular location provides significantly less ocular surface irritation and risk of extrusion than punctal plugs. These absorbable materials may carry less risk of infection, untoward inflammation, and permanent canalicular obstruction compared to permanent materials.

NONABSORBABLE INSERTS: PUNCTAL PLUGS

The original permanent punctal plug described by Freeman in 1975 resembled an asymmetric dumbbell configuration. When placed properly, these plugs sit visibly at the punctum, with a wide internal anchoring bulb portion that prevents extrusion, and an external cap or collar that prevents the plug from descending into the canaliculus. A narrow cylindrical shaft connects the bulb and the collar. This basic punctal plug design preserves the remaining secreted tears against the ocular surface.

Design Variations

Recent modifications to the component sections and materials have improved comfort and fit while minimizing risks of spontaneous loss, extrusion, or downward migration.

Focus Point #3

Newer absorbable materials offer longer relief of dry eye symptoms.

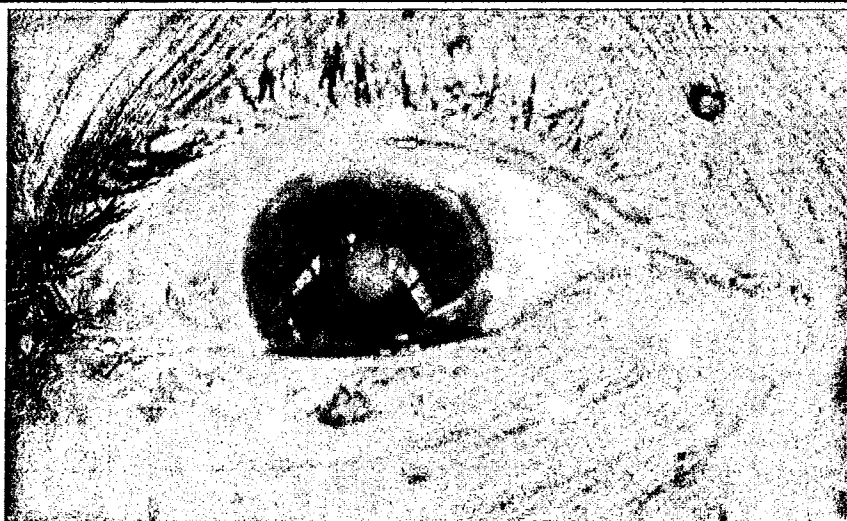


Fig. 2. External photograph demonstrates erythema and edema consistent with acute canaliculitis in the area of a previously placed canalicular plug. The infection resolved after a course of topical and oral antibiotics, and surgical removal of the occlusive device.

Variations in the collar, such as the slanted collarette offered on some Ready-Set models (FCI Ophthalmics, Marshfield Hills, MA), may improve the profile over the punctum. This plug line also offers the Slim plug, with a smaller bulb for easier insertion.

Some plugs offer a central perforation. One version, the PVP plug (FCI Ophthalmics, Marshfield Hills, MA) is lined with polyvinylpyrrolidone to prevent mucous from occluding the lumen. This lumen may allow for some tear outflow.^{14,15} The Parasol® occluder (Odyssey Medical, Inc., Memphis, TN) is hollow, but to allow for collapse and easier fit, rather than for partial outflow. The Parasol® Plus™ offers contoured edges with a solid nose.

While the PVP plug uses a silicone-lined material, other plugs use silicone rubber to change performance characteristics. The Quintess™ plug (Cynacon/Ocusoft, Inc., Richmond, TX) offers microreservoir collarette indentations to create a barrier between the plug and the ocular surface.

Some newer plugs decrease the need for sizing. Snug Plug (FCI Ophthalmics, Marshfield Hills, MA, FDA approval pending) is a silicone

punctal plug manufactured in one universal size. The SuperEagle™ (Eagle Vision, Memphis, TN), another newer silicone plug, comes in three sizes. This plug has a tapered shaft and a flexible nose to allow for easier placement without punctal gauging.

Insertion Technique

A typical insertion technique for nonabsorbable silicone punctal plugs is described below; however, specific variations should follow manufacturer's recommendations. Topical anesthesia with a drop of 0.5% proparacaine instilled into the conjunctival cul-de-sac is usually sufficient. Some patients, however, may benefit from applying direct pressure on the punctum using a 4% lidocaine-soaked cotton applicator. Manufacturers typically offer punctal size gauging systems for their products, which can minimize the waste of trial-and-error techniques. Optimal sizing balances the risk of extrusion and downward migration for plugs that are too small with the risk of pyogenic granuloma formation and discomfort associated with plugs that are too big.³⁴⁻³⁶ The ideal plug size should fit with gentle pressure.

Focus Point #4

Several newer conforming intracanalicular plugs offer improved symptoms with less risk of irritation.

The punctum is dilated by inserting the dilator vertically into the punctal os, then directing it medially with lateral tension on the eyelid. Immediately after dilation, the nose of the punctal plug is inserted vertically into the punctal os until it slips into the ampulla and the plug rim rests flush with the lid surface. After releasing the plug from the dispenser, proper fit and positioning is confirmed under the slit lamp.

INTRACANALICULAR PLUGS**Nonconforming (Horizontal Canaliculus)**

Herrick Lacrimal Plugs® (HLP) (Lacrimedics, Inc., Eastsound, WA) are cone-shaped silicone plugs for insertion into the horizontal canaliculi. No dilation is typically required, and insertion is usually well tolerated. Complications include canalicular inflammation or infection.^{35,37,38} Removal requires more invasive measures, including surgical intervention.³⁹ In a Lacrimedics, Inc.-sponsored study, 7% of patients reported wishing to reverse the procedure due to intolerable epiphora.²⁷ Saline perfusion may resolve the symptoms in the majority of patients²⁷; however, some may require surgical intervention.⁴⁰

Conforming (Vertical Canaliculus)

Conforming intracanalicular plugs represent the most recent entrants into the canalicular occlusion market. These plugs morph to the shape of

the canaliculus, resting at the junction of the vertical and horizontal canaliculus. With proper insertion, the expanded plug remains just beneath the surface of the punctum. For patients unable to tolerate standard plugs, particularly those with lid laxity or dilated puncta at high risk of extrusion, the customized fit offers a valuable nonsurgical option.

Conforming plugs rely upon the physical properties of the canalicular mucosa to induce shape change. Form Fit™ (Oasis Medical, Glendora, CA) produces an expanding intracanalicular plug that absorbs up to 20 times its weight in tears over 10 minutes. SmartPlug™ (Medenium, Irvine, CA) is a thermosensitive acrylic polymer rod that softens and molds upon warming to body temperature. These plugs require no dilation or separate sizes. Similar to the nonconforming plugs, reversal may prove challenging in some patients.

Complications of Lacrimal Occlusive Devices

Standard nonabsorbable plugs can cause mechanical conjunctivitis or keratopathy from plug collar. Subconjunctival hemorrhage has been reported to occur in up to 2% of punctal plug patients.¹⁰ Pyogenic granuloma formation can lead to discharge or plug extrusion. Intracanalicular placement minimizes the possibility of mechanical irritation. The incidence of epiphora after plug placement varies considerably due to the subjective nature of the symptom and its overlap with dry eye symptoms. Mild epiphora occurs in up to 36% of patients.⁴¹ Most patients tolerate the epiphora, but up to 5% request removal. A trial using a temporary intracanalicular plug can help predict which patients will develop epiphora if a permanent punctal plug is placed; however, it is not 100% reliable.³⁰ Migrated plugs may cause irreversible epiphora due

to canalicular stenosis or nasolacrimal duct obstruction.

Although spontaneous distal migration is uncommon due to wide rim design, improperly small punctal plugs carry a higher risk.³⁴ Migrating fragments may lodge at the junction of the common canaliculus and lacrimal sac, producing complete functional occlusion. Patients with dry eyes often tolerate this obstruction well, as it simulates an intracanalicular silicone plug. Other patients develop epiphora, canaliculitis, dacryocystitis, cellulitis, or cutaneous fistulas.^{35,38,42,43}

High-frequency B-scan ultrasound may help detect silicone punctal plugs within the canalicular system. Sonography can confirm stable intracanalicular positioning for the higher reflectivity silicone Herrick Lacrimal Plugs® and lower reflectivity acrylic polymer SmartPlugs™.⁴⁴

Removal of punctal plugs involves grasping the rim and shaft with forceps under the microscope and lifting vertically. Shaft fracture may occur resulting in downward migration of the bulb or nose portion into the canalicular system. Saline irrigation to flush the plug bulb downstream can be performed if symptomatic epiphora persists. A pigtail probe can be introduced through the opposing canaliculus to push the plug proximally out of the canaliculus. Occasionally, distal plug migration requires surgical intervention.

Various plug designs allow for stable placement in many cases, but extrusion occurs within 3 months in up to 50% of cases. Patients with pre-existing eyelid laxity and large punctae are more likely to develop early extrusion.¹⁹ Patients who have lost an

Focus Point #5

Lacrimal outflow occlusion can result in several important complications.

initial plug are twice as likely to lose a replacement plug.¹⁰ Upper punctal plugs are at greater risk of loss compared with plugs inserted in the lower puncta.^{45,46} Extrusion rates differ for different plug models. One study found that 72% of EaglePlugs™ (Eagle Vision, Memphis, TN) are lost at a mean of 59 days versus a 56% loss rate of FCI punctal plugs at a mean of 287 days.⁴⁶ Another study showed loss rate of 30.8% for Flex Plugs (Eagle Vision, Memphis, TN) at 4 months versus 68.6% for EaglePlugs™.⁴⁷ Reinsertion following extrusion usually requires a larger plug,⁴⁸ although granulation tissue occluding the canaliculus can confound reinsertion.⁴⁹ Softer polymers, such as Elast-Eon™ (AorTech, Surrey, United Kingdom) (liquid silicone/rubber elastomer), may improve comfort while reducing the incidence extrusion. Securing plugs with 10-0 polypropylene suture may improve long-term success.⁵⁰

While pyogenic granuloma formation due to silicone punctal plugs was thought to be rare, a recent report describes a higher incidence.³⁶ Mean presentation occurred approximately 5 months following insertion and typically resolved within 3 weeks of removal. The geometric shape and plug size likely influence the risk.³⁶ Coating materials, such as polytetrafluoroethylene (Teflon®, DuPont, Wilmington, DE) and hydroethyl-methacrylate (Tear Saver® Plus, CIBA Vision, Duluth, GA), may reduce tissue reactivity.

Canaliculitis and dacryocystitis can occur in patients with distal punctal plug migration, or from intracanalicular plugs (Figure 2). Treatment often requires plug removal and dacrocystorhinostomy.³⁷

Surgical Occlusion

The wider selection of reversible canalicular occlusive devices has

minimized the need for permanent occlusive surgery. For some patients, however, permanent occlusion may represent the most practical option.¹⁰ Electrocautery offers excellent long-term closure.⁵¹ Other modalities include diathermy, glues, and Argon laser, which has a peak efficacy of only 40% at 1 month, decreasing to only 33% at 6 months.^{51,52}

Conclusion

Punctal occlusion therapy often benefits patients with aqueous deficiency, providing symptomatic relief and clinically measurable improvements. However, punctal plugs represent only one tool in our armamentarium to help patients with dry eyes, and plugs do have limitations. Evidence of adaptation to punctal plugs suggests that some patients benefit only temporarily from occlusive treatment. Understanding the neuromodulatory feedback mechanisms and the role of inflammatory mediators in ocular surface disease will offer exciting new medical therapies for dry eye.

References

- Freeman JM: The punctum plug: evaluation of a new treatment for the dry eye. *Trans Sect Ophthalmol Am Acad Ophthalmol Otolaryngol* 79: 874-9, 1975
- Beetham WP: Filamentary keratitis. *Trans Am Ophthalmol Soc* 33: 413-35, 1935
- Foulds WS: Intra-canalicular gelatin implants in the treatment of keratoconjunctivitis sicca. *Br J Ophthalmol* 45: 625-7, 1961
- Lemp MA: Report of the National Eye Institute/Industry workshop on Clinical Trials in Dry Eyes. *CLAO J* 21: 221-32, 1995
- Nichols KK, Mitchell GL, Zadnik K: The repeatability of clinical measurements of dry eye. *Cornea* 23: 272-85, 2004
- Yen MT, Pflugfelder SC, Feuer WJ: The effect of punctal occlusion on tear production, tear clearance, and ocular surface sensation in normal subjects. *Am J Ophthalmol* 131: 314-23, 2001
- Mishima S, Gasset A, Klyce SD, et al: Determination of tear volume and tear flow. *Invest Ophthalmol* 5: 264-76, 1966
- Ding C, Walcott B, Keyser KT: Neuronal nitric oxide synthase and the autonomic innervation of the mouse lacrimal gland. *Invest Ophthalmol Vis Sci* 42: 2789-94, 2001
- Kovács I, Ludány A, Koszegi T, et al: Substance P released from sensory nerve endings influences tear secretion and goblet cell function in the rat. *Neuropeptides* 39: 395-402, 2005
- Tai MC, Cosar CB, Cohen BJ, et al: The clinical efficacy of silicone punctal plug therapy. *Cornea* 21: 135-9, 2002
- Huang TC, Lee DA: Punctal occlusion and topical medications for glaucoma. *Am J Ophthalmol* 107: 151-5, 1989
- Fraunfelder FT: Drug-Induced Ocular Side Effects and Drug Interactions. Philadelphia, Lea & Febiger, 1989, ed 3, p 595
- Battat L, Macri A, Dursun D, et al: Effects of laser in situ keratomileusis on tear production, clearance, and the ocular surface. *Ophthalmology* 108: 1230-5, 2001
- Malet T, Challier B, David N, et al: Clinical and scintigraphic comparison of silicone and polyvinylpyrrolidone coated silicone perforated plugs. *Br J Ophthalmol* 82: 1416-9, 1998
- Bohlman H: Perforated punctal plug in the treatment of partial punctal stenosis. *Optometry* 74: 524-8, 2003
- Schirmer O: Study of physiology and pathology of tear film and tear production. *Graefes Arch Clin Exp Ophthalmol* 56: 197-291, 1903
- Kim J, Foulks GN: Evaluation of the effect of lissamine green and rose bengal on human corneal epithelial cells. *Cornea* 18: 328-32, 1999
- Tseng SC: Staging of conjunctival squamous metaplasia by impression cytology. *Ophthalmology* 92: 728-33, 1985
- Willis RM, Folberg R, Krachmer JH, et al: The treatment of aqueous-deficient dry eye with removable punctal plugs. A clinical and impression-cytologic study. *Oph-*

- thalmology 94: 514-8, 1987
20. Ishida R, Kojima T, Dogru M, et al: The application of a new continuous functional visual acuity measurement system in dry eye syndromes. Am J Ophthalmol 139: 253-8, 2005
 21. Miyata K, Otani S, Miyai T, et al: Atelocollagen punctal occlusion in dry eye patients. Cornea 25: 47-50, 2006
 22. Farrell J, Patel S, Grierson DG, et al: A clinical procedure to predict the value of temporary occlusion therapy in keratoconjunctivitis sicca. Ophthalmic Physiol Opt 23: 1-8, 2003
 23. Reese V, Youngbar PR: The effect of punctal occlusion on tear lactoferrin in aqueous deficient dry eye patients. Adv Exp Med Biol 506: 1269-71, 2002
 24. Gilbard JP, Rossi SR, Azar DT, et al: Effect of punctal occlusion by Freeman silicone plug insertion on tear osmolarity in dry eye disorders. CLAO J 15: 216-8, 1989
 25. Chalmers RL, Begley CG, Edrington T, et al: The agreement between self-assessment and clinician assessment of dry eye severity. Cornea 24: 804-10, 2005
 26. Neves RA, Doucas A, Chamon W, et al: Provisional occlusion of lacrimal puncta with catgut suture. Arq Bras Oftalmol 55: 218-20, 1992
 27. Herrick RS: A subjective approach to the treatment of dry eye syndrome. Adv Exp Med Biol 350: 571-6, 1994
 28. Murube J, Murube E: Treatment of dry eye by blocking the lacrimal canaliculi. Surv Ophthalmol 40: 463-80, 1996
 29. Altan-Yaycioglu R, Gencoglu EA, Akova YA, et al: Silicone versus collagen plugs for treating dry eye: results of a prospective randomized trial including lacrimal scintigraphy. Am J Ophthalmol 140: 88-93, 2005
 30. Glatt HJ: Failure of collagen plugs to predict epiphora after permanent punctal occlusion. Ophthalmic Surg 23: 292-3, 1992
 31. Onodera J, Saito A, George J, et al: Application of atelocollagen solution for lacrimal duct occlusion. Adv Exp Med Biol 506: 1277-81, 2002
 32. Hamano T: Atelocollagen punctal occlusion for the treatment of the dry eye. Adv Exp Med Biol 506: 1283-4, 2002
 33. Knapp TR, Kaplan EN, Daniels JR: Injectable collagen for soft tissue augmentation. Plast Reconstr Surg 60: 398-405, 1977
 34. Maguire LJ, Bartley GB: Complications associated with the new smaller size freeman punctal plug. Case report. Arch Ophthalmol 107: 961-2, 1989
 35. Rumelt S, Remulla H, Rubin PA: Silicone punctal plug migration resulting in dacryocystitis and canaliculitis. Cornea 16: 377-9, 1997
 36. Kim BM, Osmanovic SS, Edward DP: Pyogenic granulomas after silicone punctal plugs: a clinical and histopathologic study. Am J Ophthalmol 139: 678-84, 2005
 37. Takemura M, Yokoi N, Nakamura Y, et al: [Canaliculitis caused by Actinomyces in a case of dry eye with punctal plug occlusion]. Nippon Ganka Gakkai Zasshi 106: 416-9, 2002
 38. Yokoi N, Okada K, Sugita J, et al: Acute conjunctivitis associated with biofilm formation on a punctal plug. Jpn J Ophthalmol 44: 559-60, 2000
 39. Lee J, Flanagan JC: Complications associated with silicone intra-canalicular plugs. Ophthal Plast Reconstr Surg 17: 465-9, 2001
 40. Jones CE, Anklesaria M, Gordon AD, et al: Retrospective safety study of the herrick lacrimal plug: a device used to occlude the lacrimal canaliculus. CLAO J 28: 206-10, 2002
 41. Kojima K, Yokoi N, Nakamura Y, et al: [Outcome of punctal plug occlusion therapy for severe dry eye syndrome]. Nippon Ganka Gakkai Zasshi 106: 360-4, 2002
 42. Fayet B, Assouline M, Hanush S, et al: Silicone punctal plug extrusion resulting from spontaneous dissection of canalicular mucosa: A clinical and histopathologic report. Ophthalmology 108: 405-9, 2001
 43. Sugita J, Yokoi N, Fullwood NJ, et al: The detection of bacteria and bacterial biofilms in punctal plug holes. Cornea 20: 362-5, 2001
 44. Tost FH, Darman J, Clemens S: 20-MHz ultrasound and its value in imaging of lacrimal plugs. Ophthalmologica 218: 14-9, 2004
 45. Balaram M, Schaumberg DA, Dana MR: Efficacy and tolerability outcomes after punctal occlusion with silicone plugs in dry eye syndrome. Am J Ophthalmol 131: 30-6, 2001
 46. Sakamoto A, Kitagawa K, Tatami A: Efficacy and retention rate of two types of silicone punctal plugs in patients with and without Sjögren syndrome. Cornea 23: 249-54, 2004
 47. Nishii M, Yokoi N, Komuro A, et al: [Clinical investigation of extrusion of a new punctal plug (Flex Plug)]. Nippon Ganka Gakkai Zasshi 108: 139-43, 2004
 48. Inagaki K, Yokoi N, Nishii M, et al: [Study of change of size of the punctum before insertion and after extrusion of a punctal plug and selection of an appropriate plug for reinsertion]. Nippon Ganka Gakkai Zasshi 109: 274-8, 2005
 49. Nishii M, Yokoi N, Komuro A, et al: [Comparison of extrusion rate for two different design of punctal plugs]. Nippon Ganka Gakkai Zasshi 107: 322-5, 2003
 50. Obata H, Ibaraki N, Tsuru T: A technique for preventing spontaneous loss of lacrimal punctal plugs. Am J Ophthalmol 141: 567-9, 2006
 51. Hutnik CM, Probst LE: Argon laser punctal therapy versus thermal cautery for the treatment of aqueous deficiency dry eye syndrome. Can J Ophthalmol 33: 365-72, 1998
 52. Patten JT: Punctal occlusion with n-butyl cyanoacrylate tissue adhesive. Ophthalmic Surg 7: 24-6, 1976

The authors reported no proprietary or commercial interest in any product mentioned or concept discussed in this update.